

Surgical and orthotic possibilities of bone tumour pain management

Chaloupka, R., Grosman, R., Repko, M., Tichý, V.

Extremities

Imminent pathological fracture - extensive osteolytic lesion.

Mechanical bone strength decreases, microfractures develop.

Significant increasing of pain.

Risk of pathological fracture in bone metastases of carcinoma is described by Mirels score

Points	1	2	3
Localisation	Upper extremity	Lower extremity	peritrochanteric
Pain	mild	middle	severe
Metastasis type	plastic	mixed	lytic
Extent – given by ratio: lesion diameter / bone width	$< 1/3$	$1/3-1/2$	$> 2/3$

Probability of pathological fracture increasing with the score more than 7 points.

- score to 7 points - no need of prophylactic osteosynthesis (cons. tx) fract 4%
- 8 points - border line for indication of preventive osteosynthesis 15%
- 9 and more - preventive osteosynthesis in all cases 33%

lesion localisation, extent, character and pain :

5 % of lesions with extent 1/3–2/3 bone width caused pathological fracture.

81 % of lesion with extent more than 2/3 bone width caused pathological fracture.

osteolytic lesions cause pathological fracture in 48 %,

mixed metastasis in 32 %

osteoplastic metastasis rarely.

Corticalis defects (erosion) of femur and humerus increase the risk of pathological fractures significantly

Extremity pain is caused by

- Tumour expansion
- Lesion and surrounding tissues
oedema
- Increased intraosseal pressure

Pain increased by stress / load

- Advanced disease
- Mechanical bone weakness
- Patological fracture present

According to Mirels: in 90 % of cases the extent of lesion was more than 2/3 of bone width.

Lesions with mild or middle pain caused pathological fracture only in 10 %.

The lowest risk of fracture :

metastases of breast cancer, cervix
uteri, myeloma.

The highest risk:

metastases of lung cancer.

Ris of fracture increases with

- age
- degree of total and local osteoporosis

High percentage of carcinomas have metastases to peritrochanteric region - high claim to mechanical strength - high number of pathological fractures in this region.

Pathological fracture

- drift of tumour cells to blood circulation
- origin of metastases
- prognosis worsening in primary bone tumours
- increasing of mortality in cancer metastases

According to Mirels:

mortality to 6 months in pathological fracture – lung carcinoma 100%,

breast carcinoma 50%.

Goals of surgeries

- pain removal - relief
- return - improving extremity function
- improve of nursing care

Indication

- pts condition
- life expectancy
- disease stage

ABSOLUTE - unstable pathological
fracture

Indications

RELATIVE

- imminent fracture in osteolytic lesion
- painful osteolytic lesion, no response to conservative tx
- progressive osteolytic lesion (unsuccessful radio- and chemotherapy)
- significant deformity (goal – lesion decreasing – „debulking“)

Fracture stabilization:

Orthopaedic examination as soon as possible,

limb saving surgeries prevail.

Life expectancy 3-6 months

Intramedullary nail

femur, tibia, humerus, forearm – palliative surgery

– without removal of tumour lesion, healing is impossible

- risk of tumour spread significantly increases

Life expectancy more than 3-6 months

Diaphyses – lesion resection, replacement by autograft or bone cement followed by plate **osteosynthesis**.

Early active physiotherapy (osteoporosis and muscle hypotrophy prevention).

Epiphyses - resection and replacement by standard or tumour **endoprostheses** (proximal and distal femur, proximal tibia, proximal humerus).

Special tumour endoprostheses - bone cemented. After proximal humerus replacement – limited motion (less than in TKA - knee or THA - hip).

Limb saving surgeries prevail.

Amputation and exarticulation – rare in metastatic lesions – pressure sores, loss of function, unbearable pain.



Surgeries – regional orthopaedic
departments and university departments

Prosthetic management

Orthoses – shoulder – Desault type

Extremities surgery

Pathological fracture

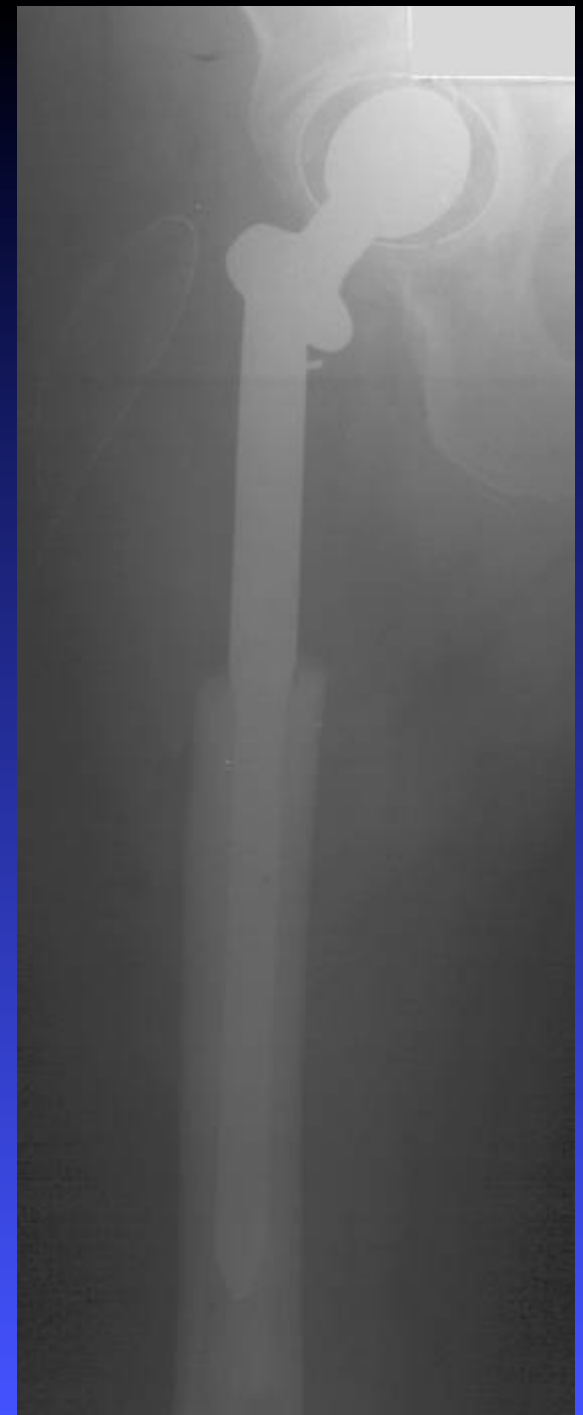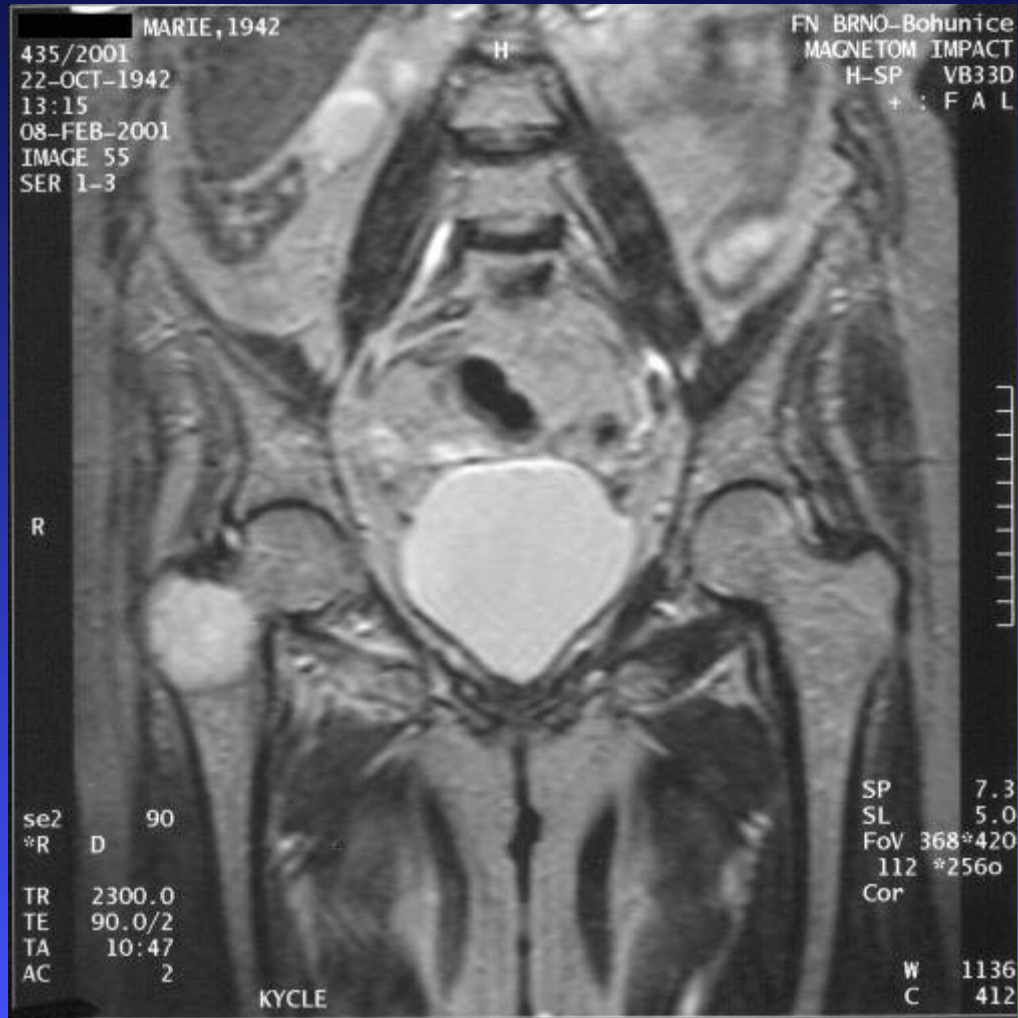- imminent
- present

X-rays in both projections
(AP and lateral)
CT, MRI

Lytic lesion more than $\frac{2}{3}$ of bone width

81% of pathological fractures

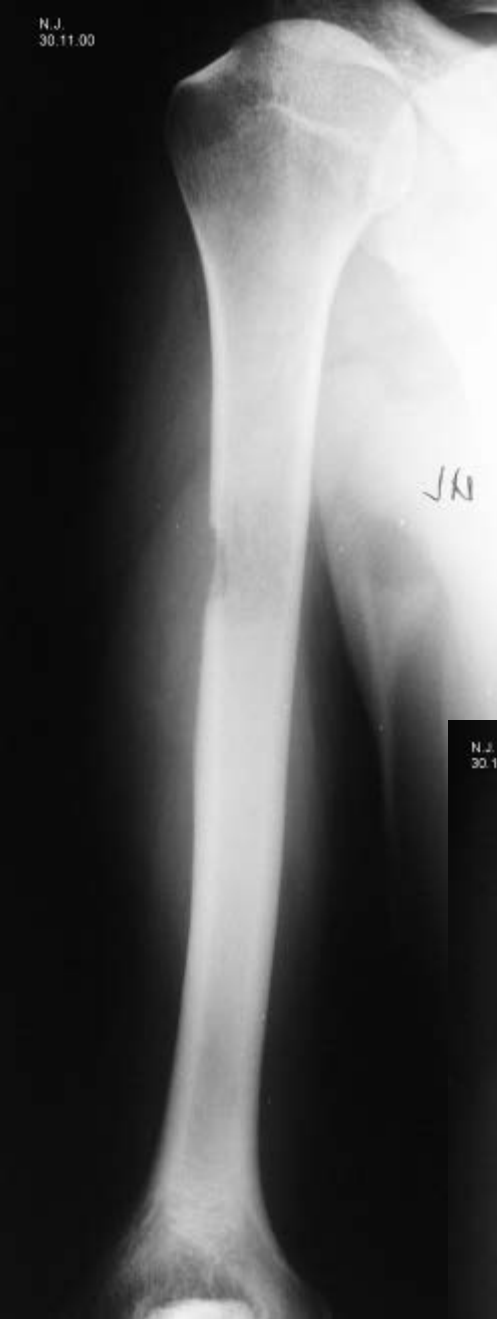Epiphyses, metaphyses – hip Tumour endoprostheses



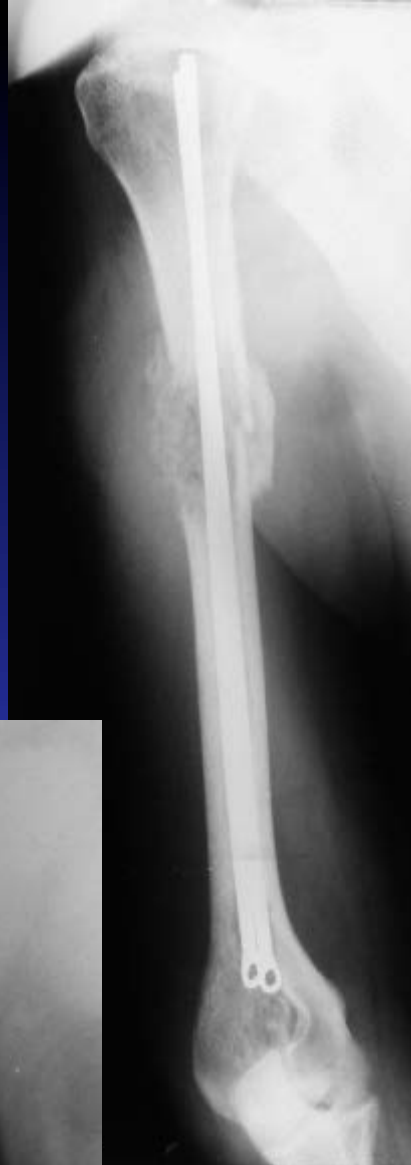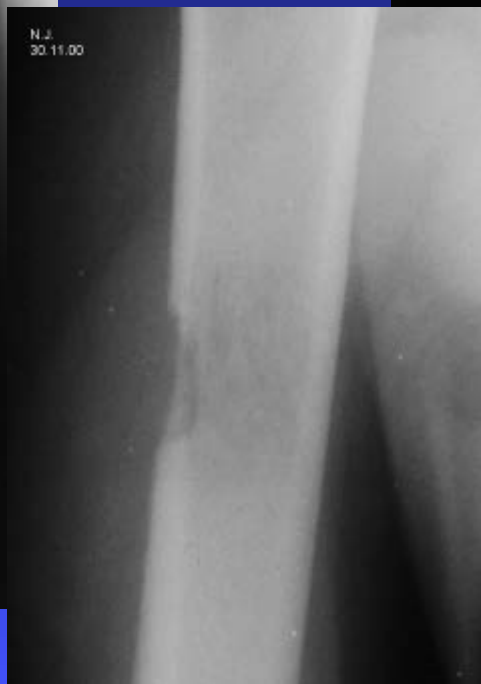Bone diaphyses

- nail
- plate with lesion resection and bone cement replacement

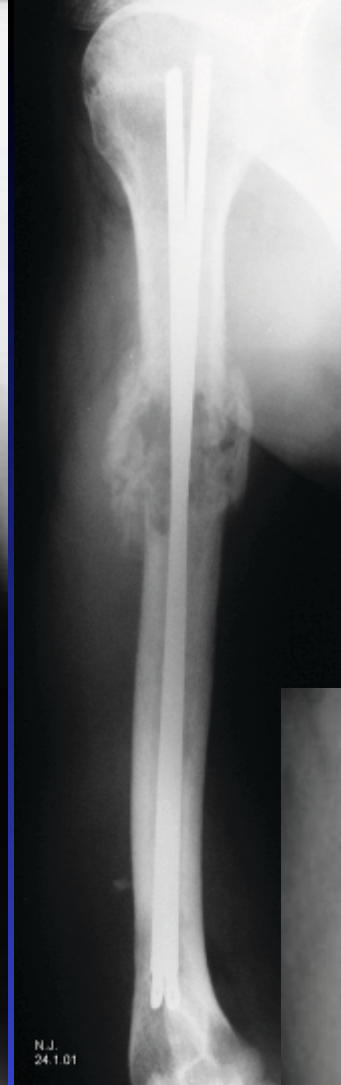
N.J.
30.11.00



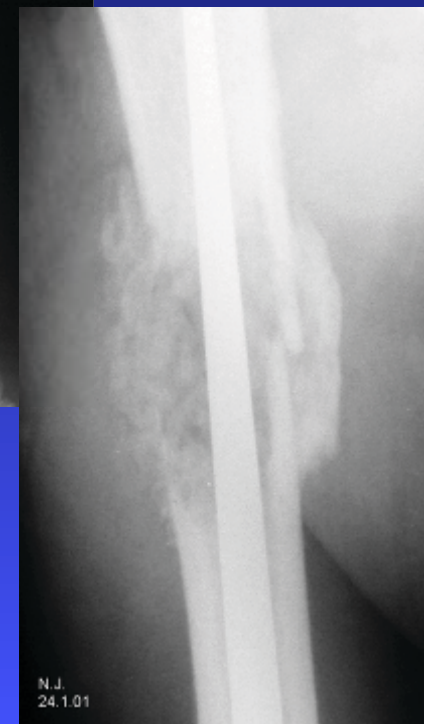
N.J.
30.11.00



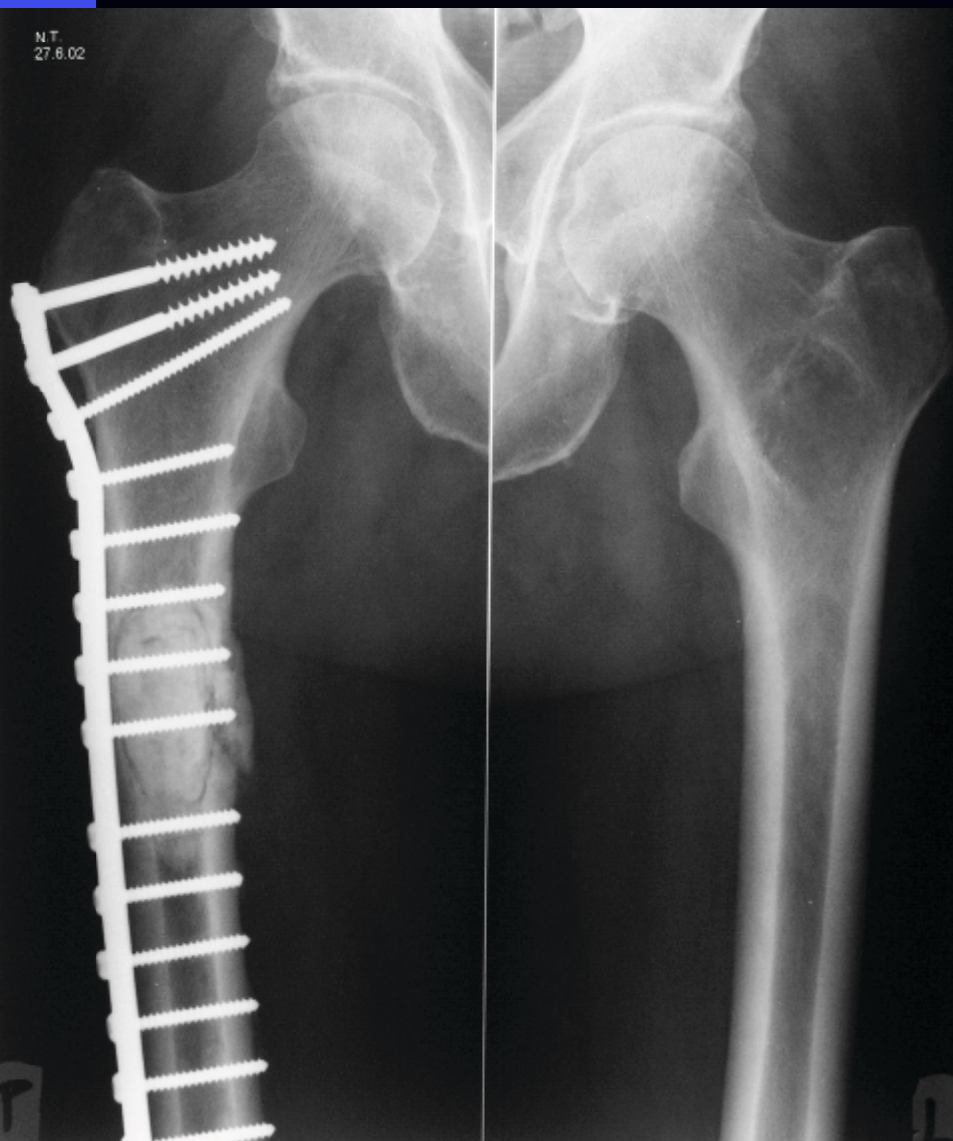
N.J.
24.1.01



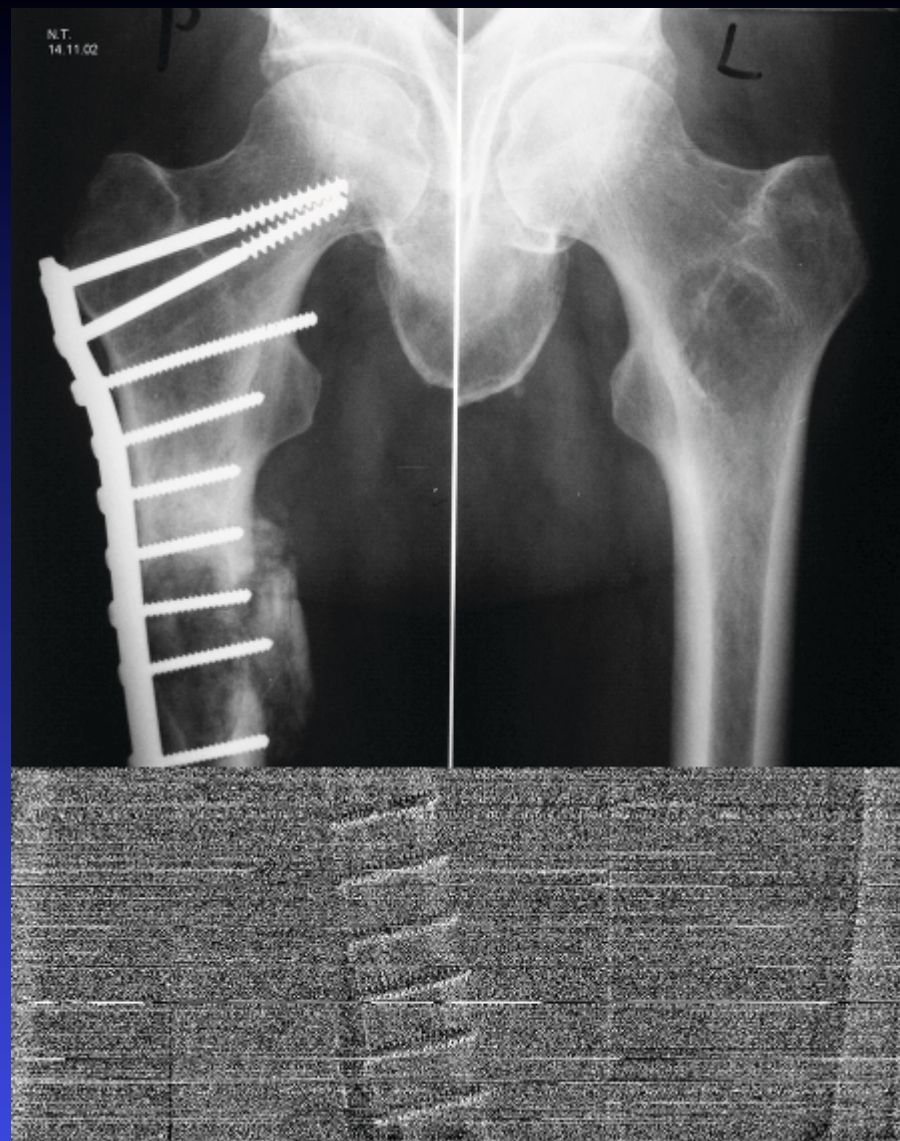
N.J.
24.1.01

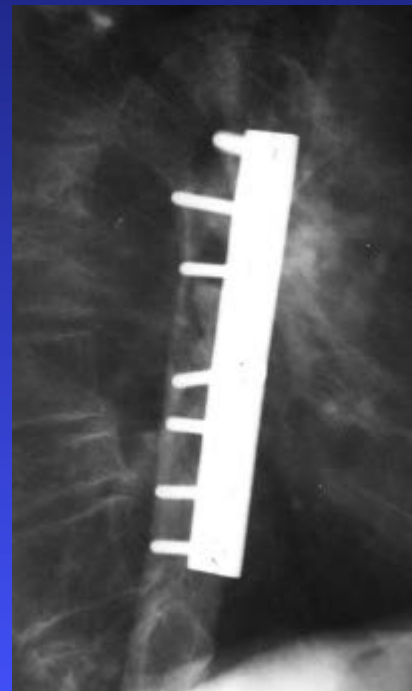
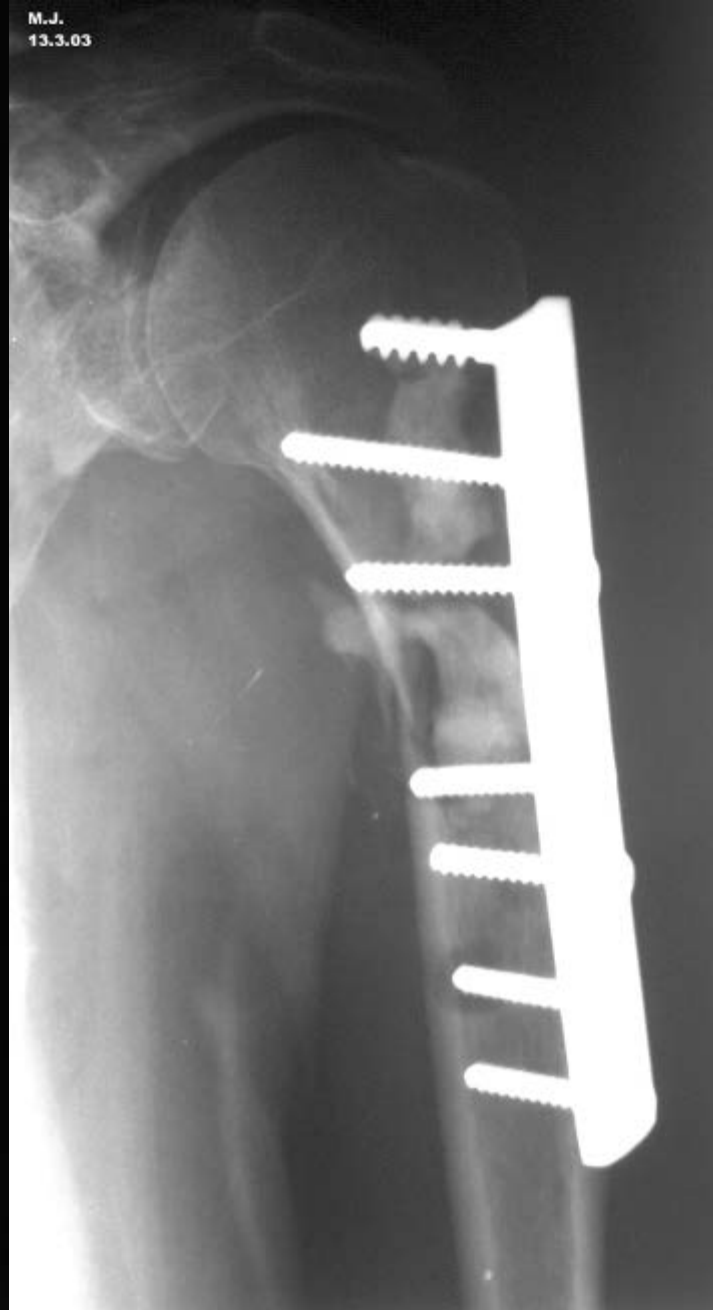
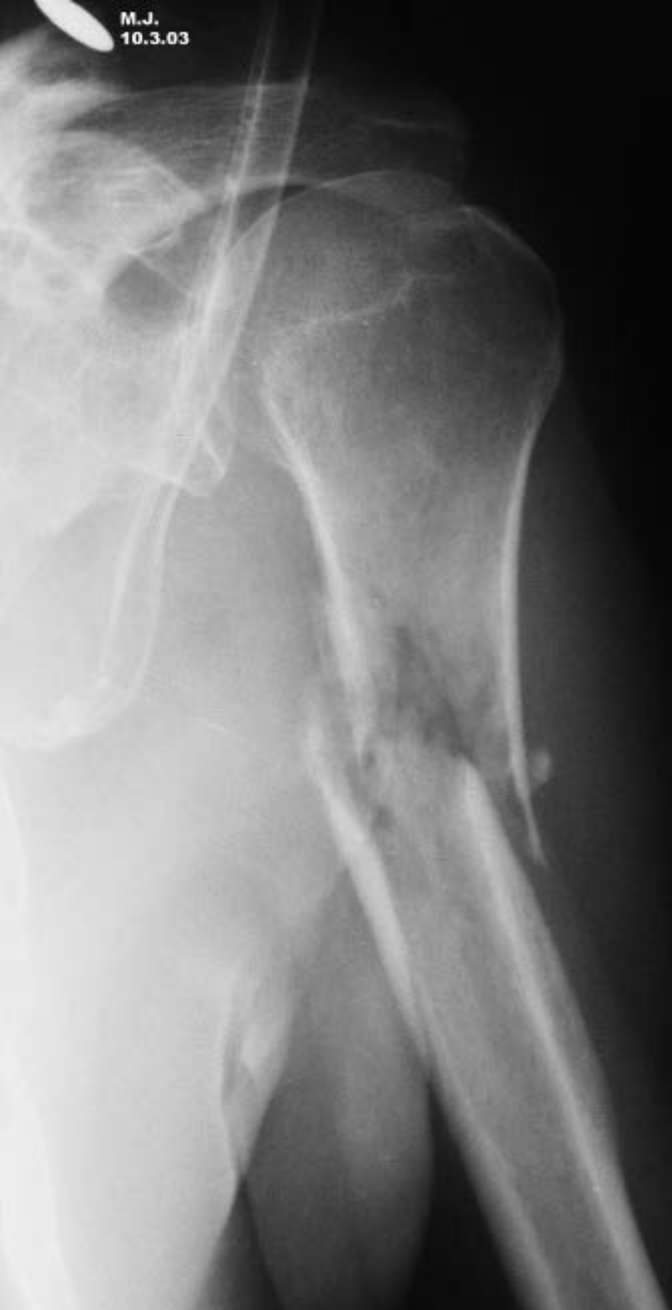

N.T.
27.6.02



N.T.
14.11.02





Spine

Pain is caused predominantly by

- growing of tumour tissue
- nerve structures compression
- neural symptoms

Spine instability

- in extensive involvement of one or more vertebrae
- small force results in pathological fracture and neural deficit

Neural deficit

- growing of tumour and neural compression
- worsening of blood supply of spinal cord
- pathological fracture with neural compression
- combination of these mechanisms

Goals of surgeries

- prevention / improvement of neural deficit
- pain relief
- restoring spine stability
- improving quality of life

Indications

- present / imminent vertebral body collapse
- present / imminent neural deficit
- to 24 hours after plegia onset (severe paresis)
- life expectancy – 3 months minimum

Diagnostics and treatment

- see presentation:

Spinal Cord Compression in Spine Tumours
and Injuries

Percutaneous vertebroplasty

percutaneous application of cement by special needle to vertebral body – image intensifier or CT check – to strengthen vertebral body and pain relief. (in local anaesthesia and analgosedation)

Percutaneous kyfoplasty

In cases of significant vertebral body compression and kyfotisation – partial (sometimes complete) restoration of vertebral body height is possible by kyfoplasty - during first two weeks after injury. Special inflatable balloon enables vertebral body height restoration, with correction of vertebral deformity (check by CT or image intensifier). The cavity is filled by bone cement. This method is expensive.

Indications of vertebroplasty and kyfoplasty

are narrow – proved vertebrogenic pain of 1–3 vertebrae, without spinal cord or radicular deficit, irritation, without tumour spread outside vertebral bodies.

Contraindications

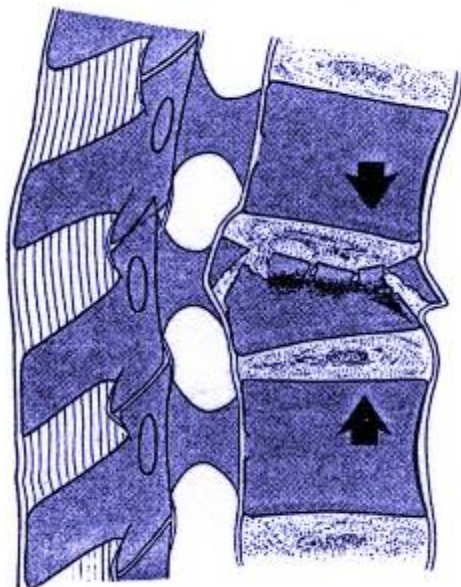
- infectious diseases
- coagulopathy
- unstable spine fractures
- collapse of vertebral body

Vertebroplasty and kyfoplasty - new methods, mainly in osteoporosis tx of Th + L spine. In oncological cases preliminary results are published.

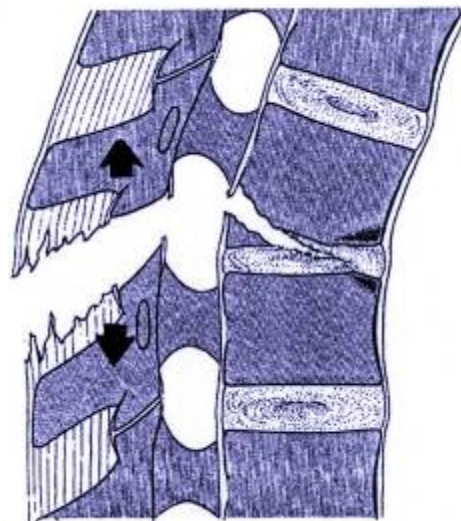
We used them, when the other surgical treatment is not possible.



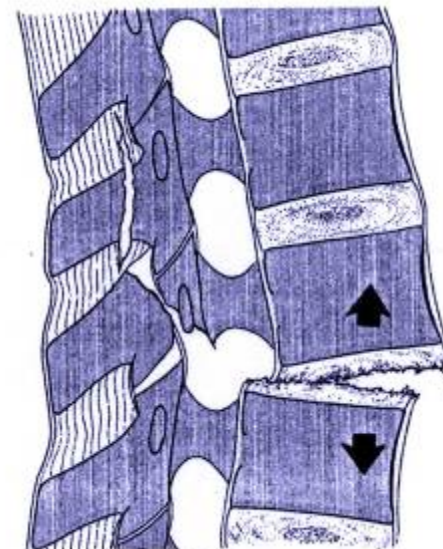
A



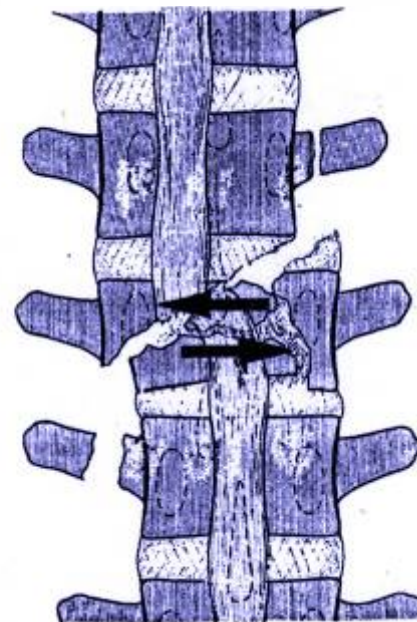
B



C



D



E

Indications: A type fracture

Osteoporotic fractures

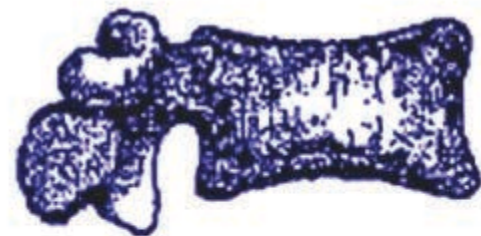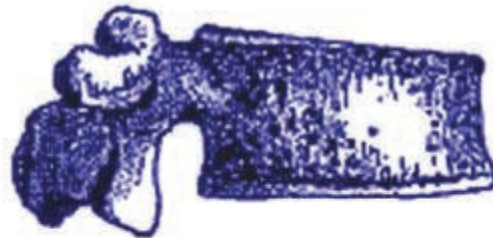Normal
(Grade 0)



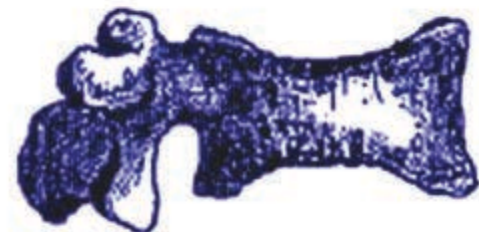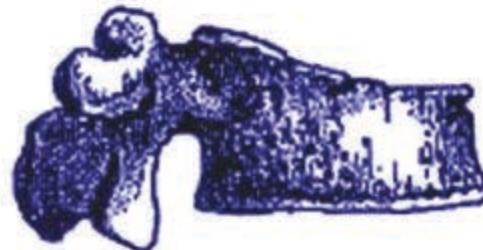Wedge deformity

Biconcave deformity

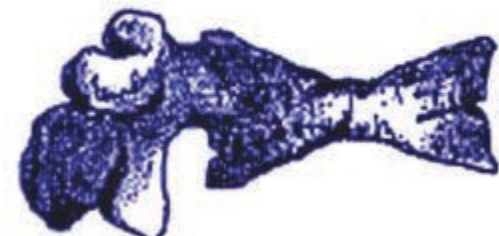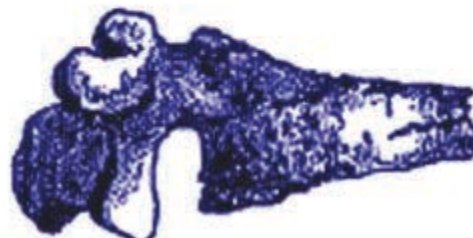Mild fracture
(Grade 1)



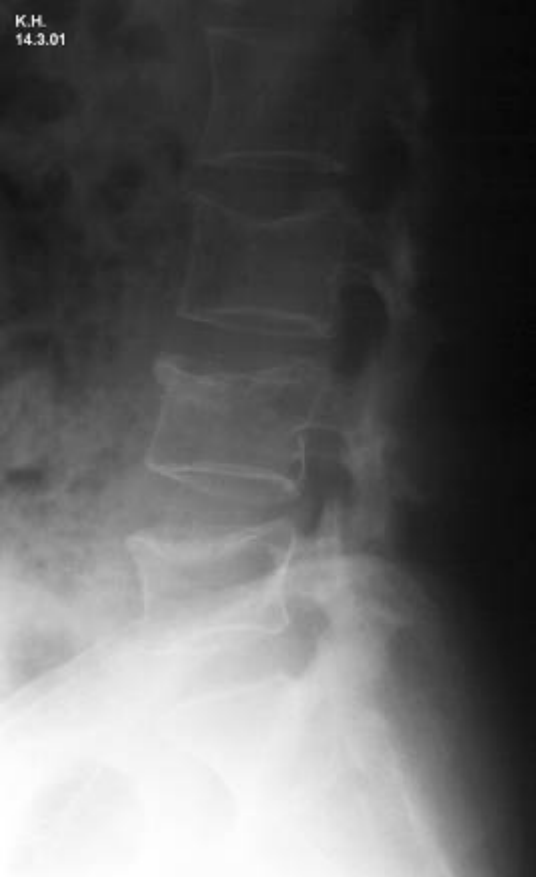Moderate fracture
(Grade 2)



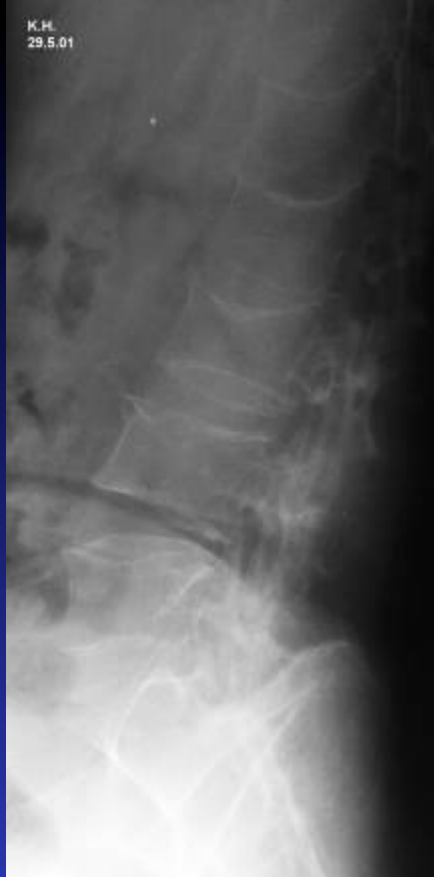Severe fracture
(Grade 3)



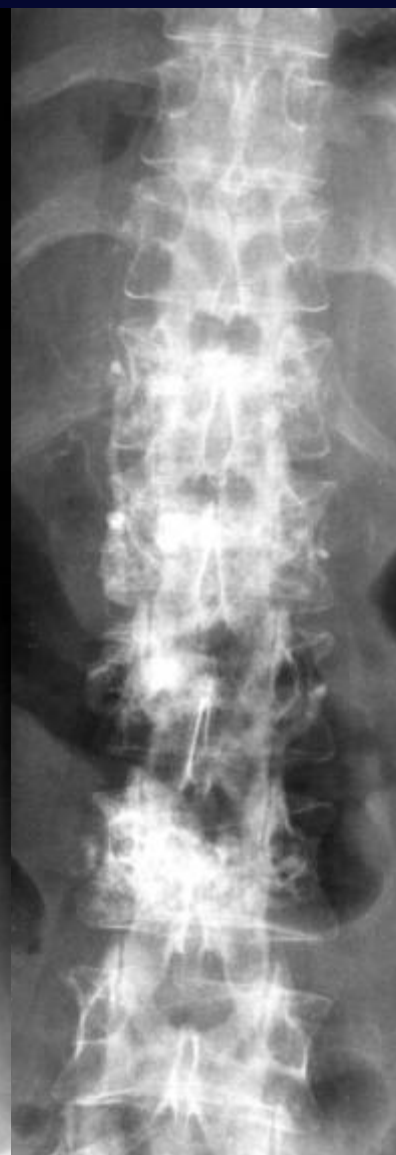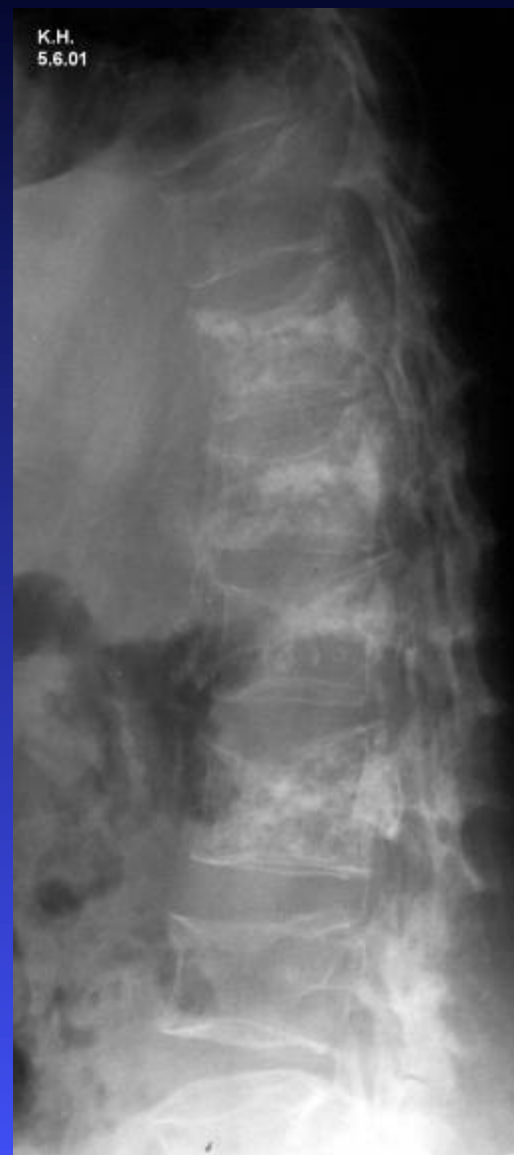
K.H.
14.3.01



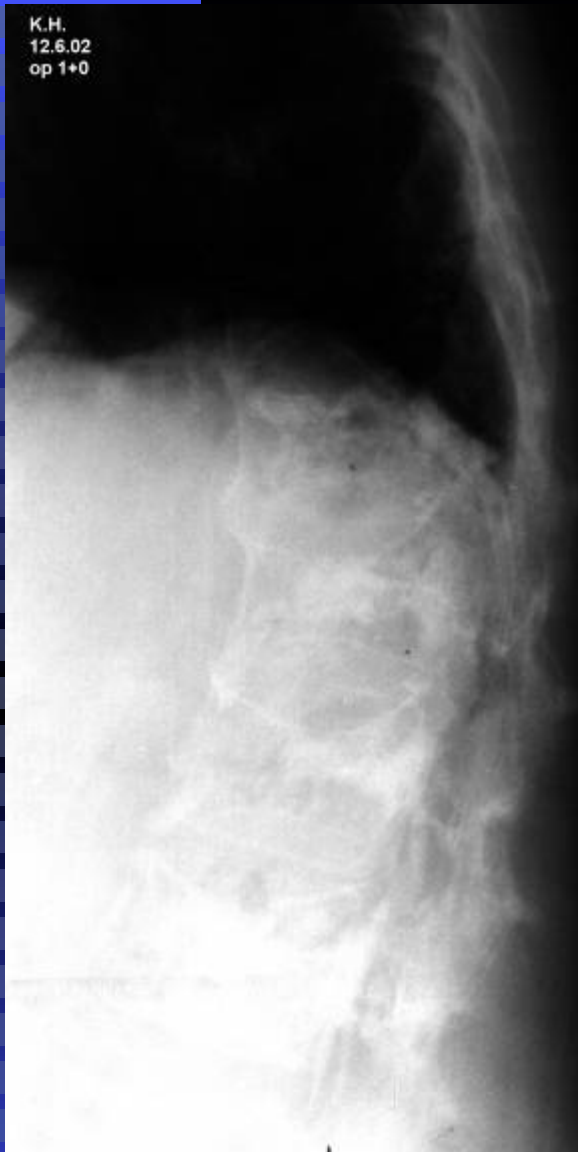
K.H.
29.5.01



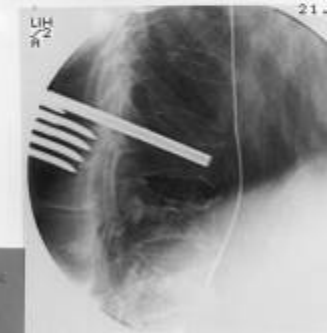
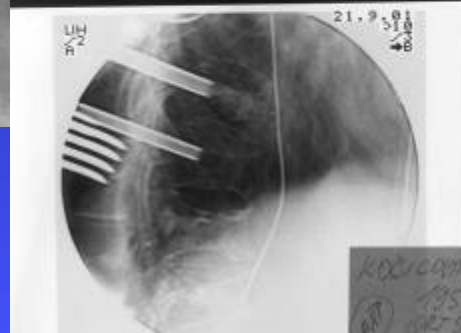
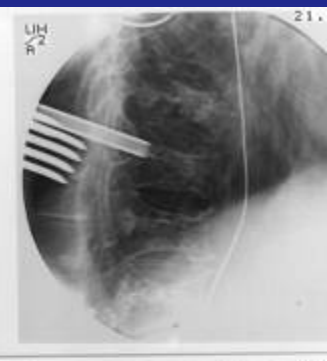
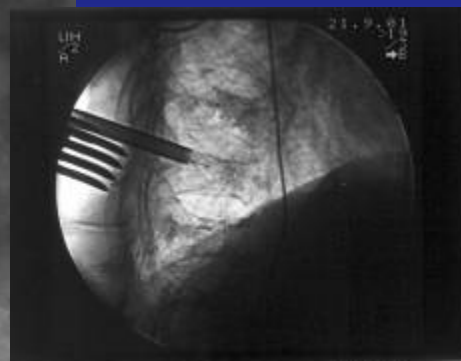
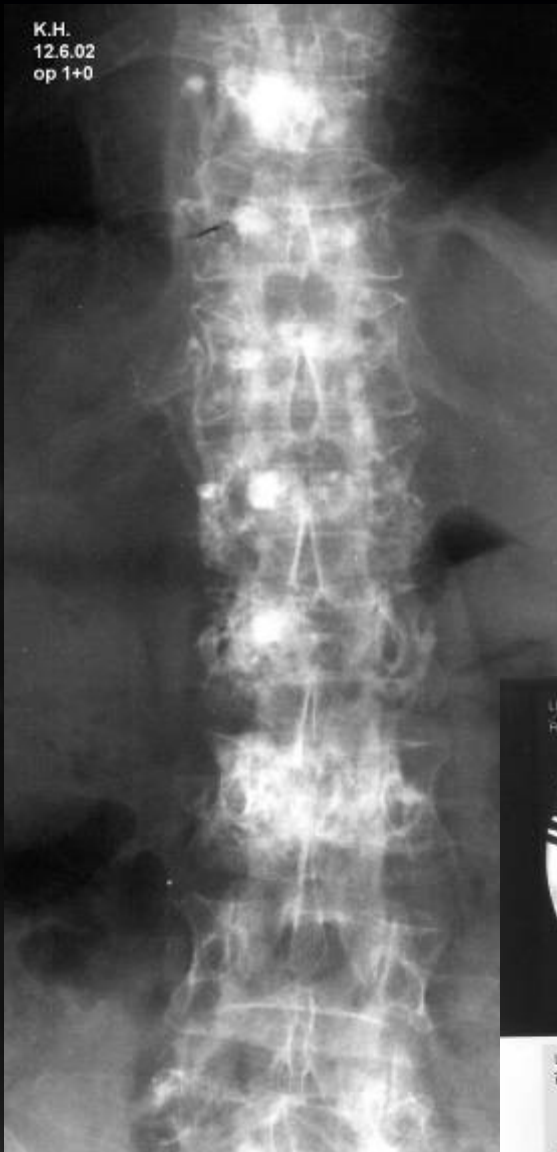K.H.
5.6.01



K.H.
12.6.02
op 1+0

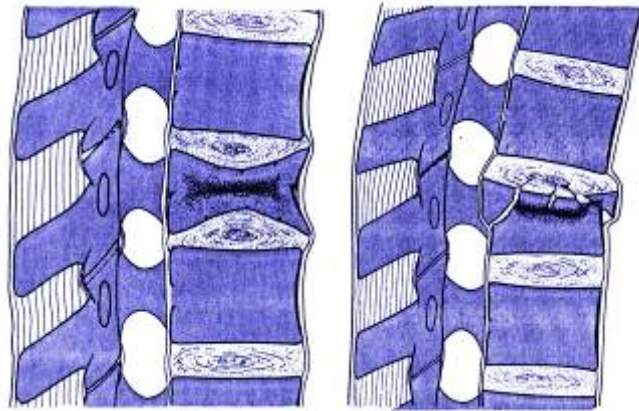


K.H.
12.6.02
op 1+0

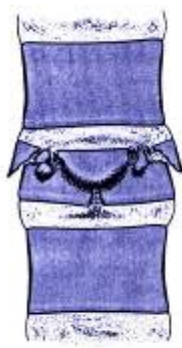

K.H.
12.6.02
op 1+0

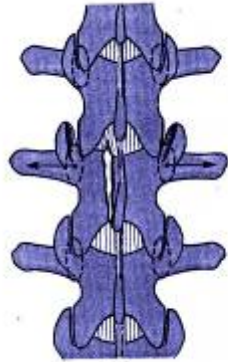
A1.3



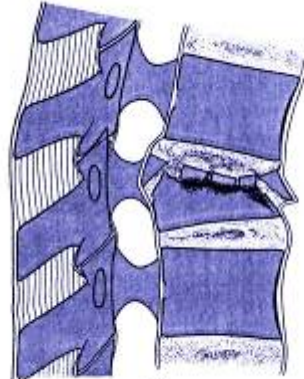
A3.1.1



A



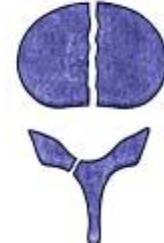B



C

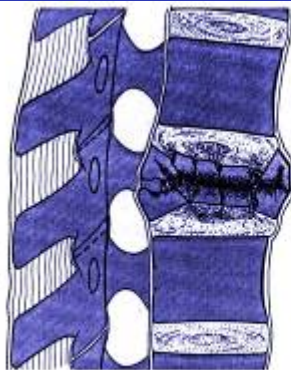


D

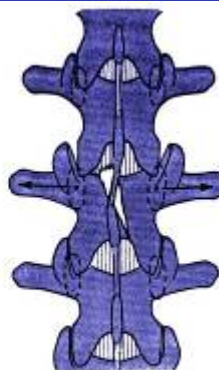


E

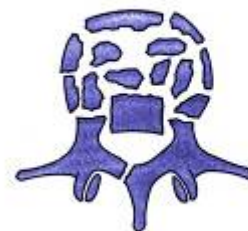A3.2.1



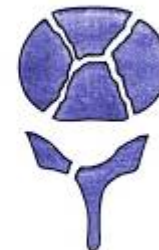A



B



C

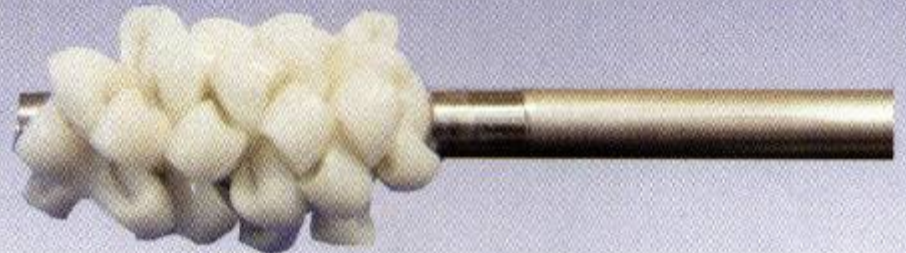

D

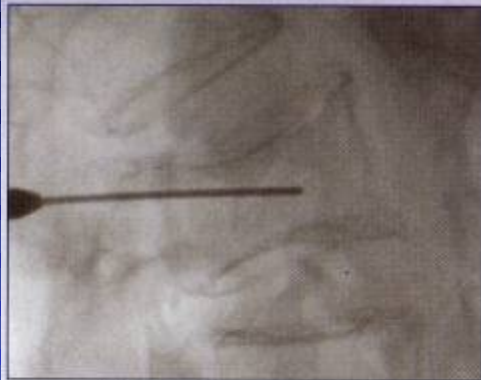
A3.3.3



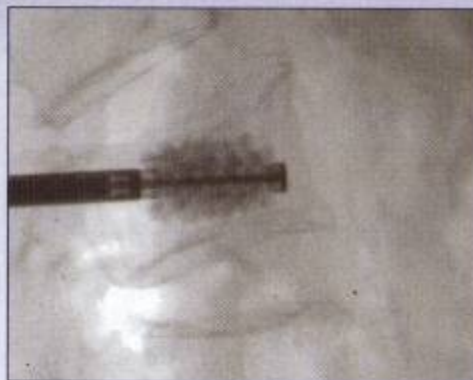SKy Bone Expander reduced



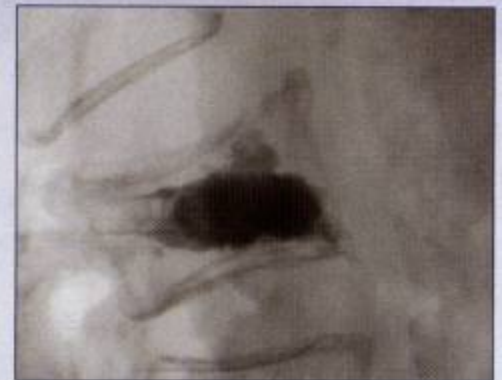SKy Bone Expander expanded



Collapsed vertebral body



Expanded SKy



Post-operative

Surgical treatment

- spondylosurgical – spine surgery departments
- specialized orthopaedic, neurosurgical,
traumatological departments
- Vertebro- a kyfoplasty – radiological departments

Prosthetic care

Orthoses – soft or Philadelphia collars,
three point orthoses – like Jewett's,
belts.

